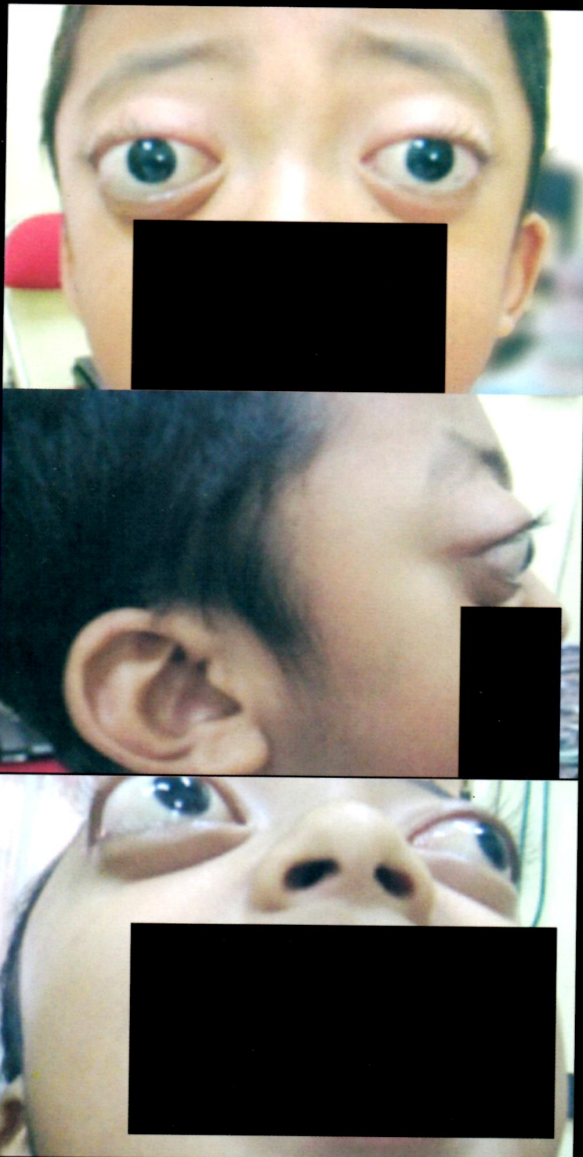



DAFTAR ISI

Visual Field Abnormality and Quality of Life of Patient with Primary Open Angle Glaucoma

The Role of Ascorbic Acid on Endothelial Cell Damage in Phacoemulsification

The Risk Factors of Human Papilloma Virus 18 on the Recurrences of Pterygium

Glaucoma Caused Blindness with Its Characteristic in Cipto Mangunkusumo Hospital

Histopathologic Profile Grading of Haematoxyline Eosin on Retinoblastoma Stadium

Decrease of Corneal Sensitivity in Patients with Diabetes Mellitus Type II

Limbal Dermoid and Pre-Auricular Tag in a 12 Years Old Girl

Management of the Complication After Silicone Fluid Injection at Facial and Eyelid Region

Vitrectomy and Silicone Oil Tamponade in the Management of Retinal Detachment in Marfan Syndrome Patient

Crouzon Syndrome

Table of Contents

No.	Title	Page
1	Limbal Dermoid and Pre-Auricular Tag in a 12 Years Old Girl	-
2	Vitrectomy and Silicone Oil Tamponade in the Management of Retinal Detachment in Marfan Syndrome Patient	-
3	Crouzon Syndrome	-
4	Histopathologic Profile Grading of Haematoxylene Eosin on Retinoblastoma Stadium	-
5	Decrease of Corneal Sensitivity in Patients with Diabetes Mellitus Type II	-
6	Glaucoma Caused Blindness with Its Characteristic in Cipto Mangunkusumo Hospital	-
7	Visual Field Abnormality and Quality of Life of Patient with Primary Open Angle Glaucoma	-
8	The Role of Ascorbic Acid on Endothelial Cell Damage in Phacoemulsification	-
9	The Risk Factors of Human Papilloma Virus 18 on the Recurrences of Pterygium	-

Limbal Dermoid and Pre-Auricular Tag in a 12 Years Old Girl

Limbal Dermoid and Pre-Auricular Tag in a 12 Years Old Girl

Author :

Maitri Anindita | maitri.anindita@yahoo.com

Department of Ophthalmology, Faculty of Medicine Airlangga University/Dr. Soetomo General Hospital, Surabaya

Rowena Ghazali Hoesin |

Abstract

The aim of this case report is to report the clinical findings of a 12-years-old girl with tumor in the left eye. She complained about a tumor in her left eye since she was born and getting bigger. She felt blurred vision and foreign body sensation in left eye since one month ago. There was no pain and no family history with tumor in the eye. On anterior segment mass in inferotemporal conjunctiva and cornea was found. The tumor had a round shape, white colour, hair and solid with diameter about 4 mm. Other anterior and posterior segment was normal in both eyes. On consultation to orthopedic department, there was no disorder in spinal cord and consultation to ENT department revealed a preauricular tag which is planned to be excised. The limbal dermoid was planned to be excised with superficial sclerokeratectomy procedure but it wasn't performed yet because this mass did not give any complaint except cosmetic problem so it will be observed for six months to evaluate the growth of the tumor.

Keyword : limbal, dermoid, pre-auricular, tag, , Goldenhar, , ,

Daftar Pustaka :

1. **Gregory L, Skuta MD, Louis B, Canor MD, Jayne S, Weiss MD, (2009).** Basic and Clinical Science Course, section 8, External Disease and Cornea. San Francisco : American Academy of Ophthalmology
2. **Paul Riordan Eva et al., (2007).** General Ophthalmology 17 th edition. New York : McGraw-Hill's company
3. **Khurana AK, (2007).** Comprehensive Ophthalmology, 4 th edition. New Delhi : New Age International
4. **Dutta LC, (2000).** Modern Ophthalmology Volume I. New Delhi : Jaypee Brothers

Limbal Dermoid and Pre-Auricular Tag in a 12 Years Old Girl

Maitri Anindita, Rowena Ghazali Hoesin

Department of Ophthalmology, Faculty of Medicine Airlangga University/Dr. Soetomo General Hospital, Surabaya

ABSTRACT

The aim of this case report is to report the clinical findings of a 12-years-old girl with tumor in the left eye. She complained about a tumor in her left eye since she was born and getting bigger. She felt blurred vision and foreign body sensation in left eye since one month ago. There was no pain and no family history with tumor in the eye. On anterior segment mass in inferotemporal conjunctiva and cornea was found. The tumor had a round shape, white colour, hair and solid with diameter about 4 mm. Other anterior and posterior segment was normal in both eyes. On consultation to orthopedic department, there was no disorder in spinal cord and consultation to ENT department revealed a preauricular tag which is planned to be excised. The limbal dermoid was planned to be excised with superficial sclerokeratectomy procedure but it wasn't performed yet because this mass did not give any complaint except cosmetic problem so it will be observed for six months to evaluate the growth of the tumor.

Key words: limbal dermoid, pre-auricular tag, Goldenhar Syndrome

Correspondence: Maitri Anindita, c/o: Departemen/SMF Ilmu Kesehatan Mata Fakultas Kedokteran Universitas Airlangga/RSUD Dr. Soetomo. Jl. Mayjen Prof. dr. Moestopo 6-8 Surabaya 60286. Email: maitri.anindita@yahoo.com

INTRODUCTION

Limbal dermoid, also known as epibulbar or conjunctival dermoid cyst is a benign congenital tumors that contains choristomatous tissues (tissues that are normally not found in these places). Limbal dermoid tumor on the surface appears round and demarcated. Commonly this tumor is found in the infero-temporal quadrant of the corneal limbus. The color of this tumor varies from white, gray, reddish yellow to brown depending on the specific tissue in the tumor mass. These tumors may contain a variety of histological tissue distorted, such as connective tissue, skin, fat, hair, sweat glands, lacrimal glands, muscles, teeth, cartilage, bone, blood vessel structures, and neural tissues, including brain. Limbal dermoid rarely becomes malignant.^{1,2,3}

Limbal dermoid is a rare case. Worldwide incidence is estimated at 1 case at 10,000 population². In studies epibulbar christoma in Goldenhar syndrome patients gained 14% of lesions located in the nasal, 86% in temporal, 16% superiorly, and 84% in the inferior.²

Limbal dermoids occur with equal frequency in men and women and no found on rasial tendency.¹

The purpose of presenting this case is to determine appropriate management actions immediately and obtaining the agreement of action to be performed on this patient considering the patient is still relatively young.

CASE REPORT

A twelve-year old girl came to Dr. Soetomo hospital with chief complain tumor in the left eye since she was born and is getting bigger. She felt her visual acuity had decreased since a month ago and foreign body sensation but no pain. She also complained about her tumor in the left ear since she was born without pain. The history of birth and developmental statue was normal, no familial history, and no trauma before.

From physical examination in left eye anterior segment we found mass in cornea with round shape Ø 4 mm, solid and hair in inferotemporal limbus. The other was normal. Funduscopy in both eyes were in normal limit. We also found mass in left auricle with round shape Ø 5 mm, rubbery solid, stemmed and no pain.

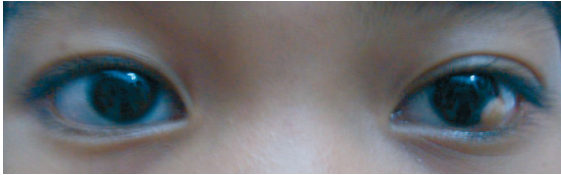

Figure 1. A girl with limbal dermid

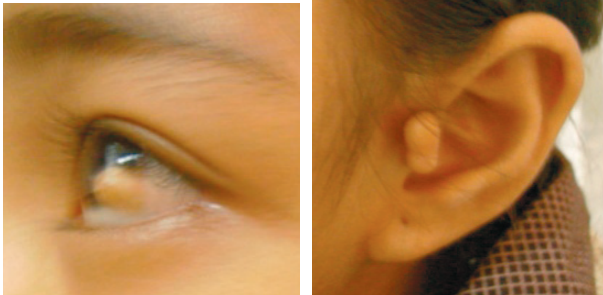

Figure 2. Limbal dermid and pre-auricular tag

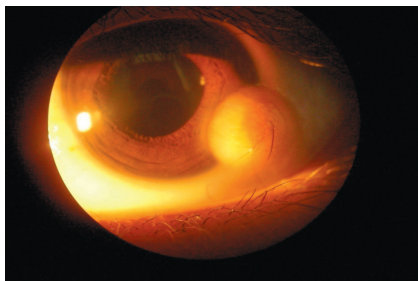


Figure 3. Hair in limbal dermid

Laboratory and chest X-Rays examination were also normal. From consultation with orthopedic department there was no disorder in spinal cord and from consultation with ENT department there was a preauricular tag which planned to be excised.

DISCUSSION

Limbal dermoid is an acquired disorder since birth, but only realized after the patients aged 1 year or more. Limbal dermoid is generally not inherited, although some exceptions have been reported.

A diagnosis of dermoid and dermolipoma was made from physical examination.¹ Limbal dermoid is usually associated with Goldenhar syndrome, the syndrome which is associated with dermoid tumors, abnormalities in the ear, and the spine (oculoaurikulovertebra).² Limbal dermoid in association with Goldenhar syndrome is an autosomal dominant.

Small size limbal dermoid usually causes no symptoms or asymptomatic, but large lesions may cause discomfort like dry eye, conjunctival irritation or lagophthalmos. Visual acuity can also be affected by the greater limbal dermoid because these lesions can affect the development of a cylindrical or penetrated into the visual axis thereby blocking the visual axis and corneal Astigmatism can be anisometropik amblyopia. Large limbal dermoid may interfere cosmetic.^{1,2,3}

The differential diagnosis with tumors was found on the conjunctiva include conjunctival hemangioma, cyst conjunctiva, conjunctival papillomas and squamous cell carcinoma of the conjunctiva.

But from the results of the anterior segment with the acquisition of a white mass with a smooth surface and covered with hair as well as the discovery of preauricular tag on the left ear, the patient is suspected of suffering from Goldenhar syndrome. Although there were no spinal abnormalities, two of the three signs of Goldenhar syndrome (Oculo-Auriculo-vertebrae) have been met.

Surgical treatment should be considered only when the risk of surgery (scar) or surgical complications are comparable with the possibility of raising the patient's vision or view cosmetic. Operation of superficial sclerokeratectomy cuts the surface of the eyeball, is a procedure of choice to remove the dermoid. The tissue must always be sent to a pathologist for examination.^{1,2,3}

But we did not perform operation to this patient because the mass did not give any complains except cosmetic problem. So we observedw it for six month about the growth of the tumor.

CONCLUSION

Limbal dermoid is a benign tumor and a rare case which must be excised carefully to prevent lekoma cornea which can close the visual axis.

REFERENCES

1. Gregory L, Skuta MD, Louis B, Canor MD, Jayne S, Weiss MD. *Basic and Clinical Science Course, section 8, External Disease and Cornea*, American Academy of Ophthalmology, San Francisco, 2009–2010 p. 275–276.
2. Paul Riordan Eva *et al. General Ophthalmology* 17th edition, McGraw-Hill's company New York, 2007 p. 126.
3. Khurana AK. *Comprehensive Ophthalmology*, 4th edition, New Age International, New Delhi, 2007 p. 86.
4. Dutta LC. *Modern Ophthalmology Volume I*, Jaypee Brothers New Delhi, 2000 p. 123.