

## Case Report

# Esthetic rehabilitation of crowded and protruded anterior dentition

Cecilia G. J. Lunardhi and Eric Priyo Prasetyo

Department of Conservative Dentistry  
Faculty of Dentistry, Airlangga University  
Surabaya - Indonesia

### ABSTRACT

**Background:** Recent trends put esthetic rehabilitation as a demanding treatment in order to correct malpositioned anterior dentition. This is enhanced by the patient's background, especially careers that require prime appearance for the public. **Purpose:** To describe that even though there are many treatment alternatives and procedures, esthetic rehabilitation on crowded and protruded anterior dentition using endodontic treatment, cast posts and all ceramic crowns, can improve patient's appearance. **Case:** This article presents a case report on esthetic rehabilitation of crowded and protruded anterior dentition. Treatment was done due to patient's refusal in receiving orthodontic treatment. The patient requested esthetic rehabilitation as an expectation for faster and instant esthetic result. **Case management:** Endodontic treatment was done to the involved dentition prior to the final restoration. Cast posts and all ceramic crowns were used as final restoration to correct the crowded and protruded anterior teeth. **Conclusion:** Esthetic rehabilitation can be done successfully on crowded and protruded anterior dentition. Instant result could be achieved by this treatment. This is supported by the fact that dentists should be aware of not only choosing the right treatment and materials but also patient's expectations and conditions.

**Key words:** esthetic rehabilitation, cast post, all ceramic crown

*Correspondence:* Cecilia G.J. Lunardhi, c/o: Departemen Konservasi Gigi, Fakultas Kedokteran Gigi Universitas Airlangga, Jl. Mayjend. Prof. Dr. Moestopo 47 Surabaya 60132, Indonesia. E-mail: ep\_prasetyo@yahoo.com

### INTRODUCTION

Esthetic rehabilitation becomes more popular and widely known in today's dynamic society. Dentists as clinicians must have logical diagnostic approach when planning an esthetic rehabilitation therefore creating esthetic dental appearance as expected by their patients.<sup>1</sup> In order to achieve optimal esthetic, dentists must really create natural appearance as natural dentition in the right arch, proper inclination and alignment to the adjacent teeth. Considering esthetic, the best material of choice for matching the natural state of a complex human dentition as in indirect anterior restoration is ceramic for the highly desirable properties in color stability, translucency, light transmission, and biocompatibility.<sup>2-4</sup>

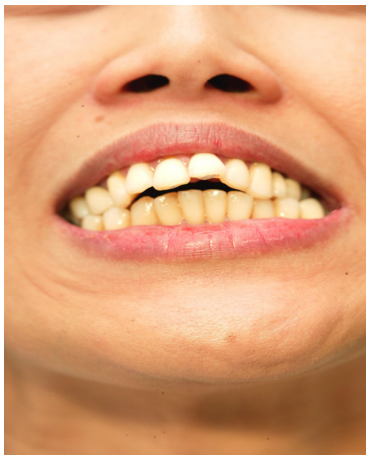In choosing the right materials, dentists should consider objective and subjective factors as well as patient's expectations, while this surely require a thorough

understanding about the art and science of esthetics thus making it a significant challenge to dentists.<sup>5</sup> In some cases, in order to correct malpositioned teeth to be in the right alignment requires decapitation of partial or all of tooth crown and restore it with indirect post, core and crown restoration. Regarding this, endodontic treatments are needed to be performed over the involved dentition, although these teeth are normally intact and in vital condition. Therefore, several important considerations in determining the post-endodontic restorations are needed and based on the protection and conservation of the remaining tooth structure to reduce pressure over teeth in restorative aspect, esthetic condition, inclination, and to achieve the natural tooth morphology.<sup>6</sup>

This article presents a case report on esthetic rehabilitation of crowded and protruded anterior dentition using endodontic treatment, cast posts, and all ceramic crowns as final esthetic restorations.

## CASE

A forty-year old female patient came with crowded and protruded anterior dentition (Figure 1). This patient worked as a public relation representative in a private company. In the first appointment, anamnesis and clinical observation were done. From anamnesis, it was found that the patient had refused orthodontic treatment since it required more time and discomfort during treatment. On clinical examination, it was found that the patient was in good health. After thorough explanations, the patient approved and consented about conservative esthetic rehabilitation procedure through conventional endodontic treatment. The restoration planning was determined using cast post and all ceramic crowns. Alginate impression was done to produce the study model and temporary crowns as provisional restoration.



**Figure 1.** Patient's anterior teeth condition before treatment.

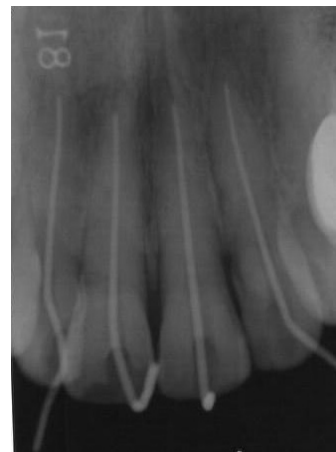## CASE MANAGEMENT

After anamnesis, clinical examination, thorough explanation, and patient's consent about esthetic rehabilitation treatment procedure, on the second visit, one visit endodontic treatment was done on four upper anterior teeth. Local infiltration anesthesia was applied on 12, 11, 21, and 22 (Citoject Heraeus). After local diagnostic wire photo was done to tooth number 12, 11, 21, and 22, endodontic treatment was performed in crown down pressureless technique (Universal Protaper Dentsply) for the cleaning and shaping of all four root canals according to the manufacturer's sequence and working lengths (central incisors 22 mm, lateral incisors 21 mm) of each root canal.

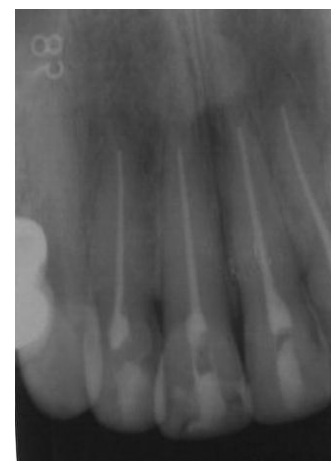Sample irrigation was done with sodium hypochlorite (ChlorCid Ultradent) between preparation sequences. Trial photo was taken to confirm the preparation and sealing of gutta point obturation (Figure 2). Obturation was done according to working lengths using single cone technique with F2 gutta point (Protaper Dentsply) and

obturation paste (Top Seal Dentsply), then obturation photo was taken (Figure 3). After the endodontic treatment was accomplished, teeth number 12, 11, 21, and 22 were decapitated and prepared for post and core.

After decapitation and post preparation, double impression was done (Panasil Kettenbach) as a mould to fabricate the Ni-Cr post and core. Bite registration record was taken, and then the impression was sent to dental laboratory with a written detailed laboratory prescription. The first temporary provisional acrylic crowns (Tempron GC) with post and core were cemented (Figure 4) using temporary cement (Freegenol GC).

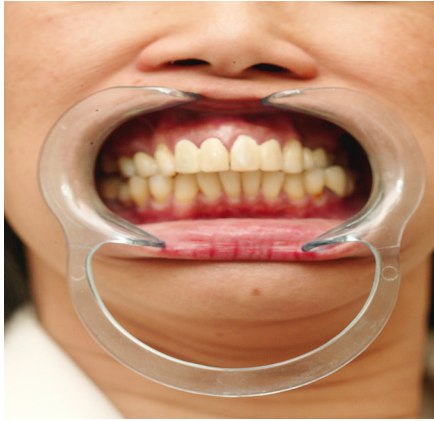

**Figure 2.** Gutta point trial photo.

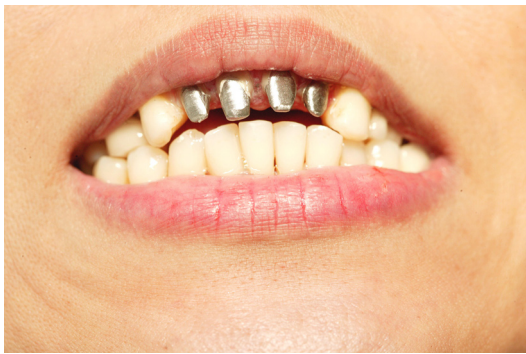

**Figure 3.** Obturation photo.

On third visit, before the temporary restoration was removed, alginate impression (Chroma Heraeus) was taken as mould for further making of direct provisional crown from acrylic (Tempron GC). There was neither patient complaint nor pain reported during one week after endodontic treatment although analgesic was not administered. After the cast posts and cores from dental laboratory were available, the temporary restoration was



**Figure 4.** Cementation of first temporary posts and crowns.

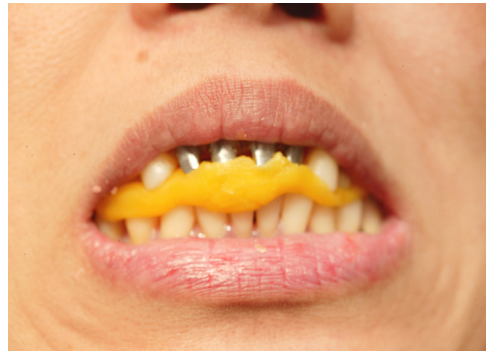

**Figure 5.** Cementation of cast posts and cores.

removed and cleaned. Cast posts and cores from the lab was cemented permanently (Figure 5) using luting cement (Fuji I GC).

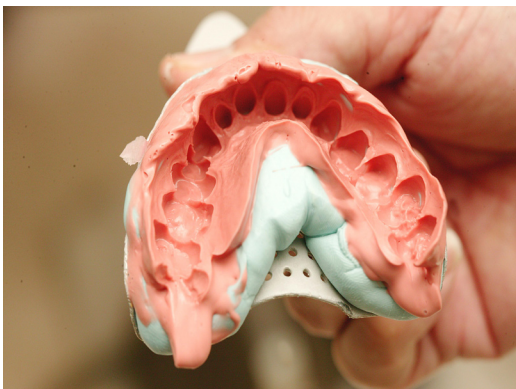
Double impression (Panasil Kettenbach) and bite registration record (Panasil Kettenbach) were done for the second time as a guide to make the final all ceramic crowns (Figure 6 & 7). Remains of the impression materials

were cleaned and the teeth were prepared for temporary provisional crowns cementation (Freegenol GC). The second temporary provisional crowns (Tempron GC) were cemented, the impression result was sent back to the dental laboratory for all ceramic crowns production along with a detailed laboratory prescription. For color mapping, a Vita shade guide of A3 was selected, as well as explicit details about what to be done regarding the anatomical morphology, normal anterior alignments, and occlusion.

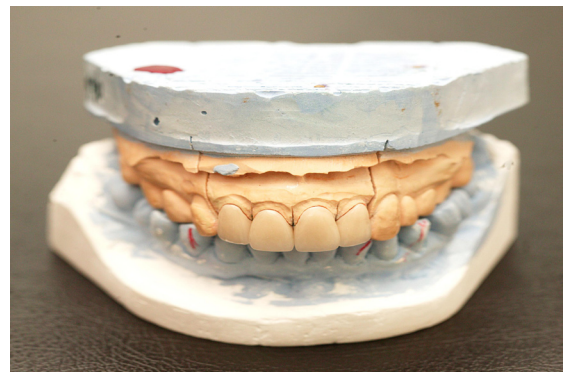


**Figure 7.** Bite registration record for the final restoration.

On the fourth visit, all ceramic crowns were available and were put on the model (Figure 8). These crowns were cemented one-by-one using resin cement (Calibra Dentsply). The excess from cementation was cleaned before full set with hand instrument and contacts of each crown were checked using dental floss (Figure 9). Occlusion and contact showed a fit state. The final result showed better teeth alignment compared to the initial condition prior to esthetic treatment hence changing the appearance and finally increase patient's self esteem (Figure 10). Patient follow ups were done 6 months and 1 year after treatment, there were no complaint and the patient was satisfied with the result.

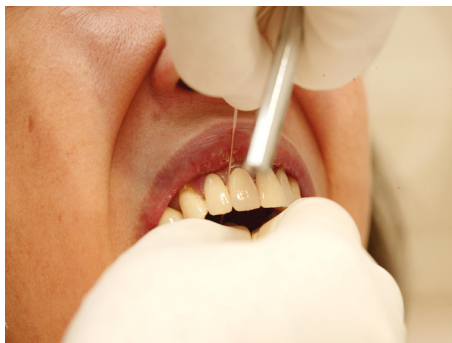

**Figure 6.** Double impression for final restoration.

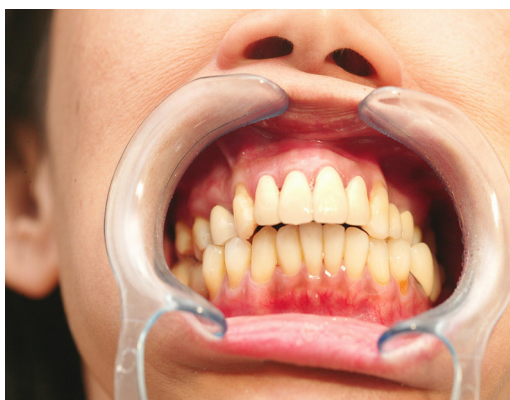

**Figure 8.** All ceramic crowns on model.





**Figure 9.** All ceramic crowns in place.



**Figure 10.** Final esthetic result.

## DISCUSSION

Esthetic rehabilitation need patient's objective and subjective considerations, because beside the high cost of treatment, it involves removal of natural tooth structures and vitality, moreover it also requires good cooperation and understanding between the patient and dentist as operator. In this case, the ideal treatment of choice to correct the crowded and protruded anterior dentition should be orthodontic treatment, but the patient refused and in the other hand, demanded a more instant esthetic result in a relatively short time. As an alternative, the patient opt the conservative esthetic rehabilitation on her crowded and protruded anterior dentition.

This case showed that crowded and protruded anterior dentition could be overcome with esthetic rehabilitation using endodontic treatment, cast posts, and all ceramic crowns in relatively short time which was only four treatment visits within one week (7 days), excluding the two follow-up visits afterwards. Cast posts were used in this case to fix the extremely protruded anterior dentition into their natural inclinations, where the use of fiber posts were notably impossible, although esthetically, fiber post has much better properties to be done on cases of normal or slightly mal-positioned tooth inclination.

Endodontic treatment (pulpectomy) was done on four upper anterior teeth under consideration of extreme mal-alignment, therefore crowns and posts as intra canal

retentions are needed to correct the position of those anterior dentition, with regard that endodontic treatment has high success rate, about 90% or even more in pulpectomy cases.<sup>6,7</sup> This is surely must be supported with proper techniques and quality post-endodontic restorations.

All ceramic crowns were chosen for better esthetics.<sup>2-5</sup> The use of all ceramic crowns has been increasing in strength and popularity. This is supported with the newly developed materials such as Zirconia and the invention of CAD/CAM technology.<sup>8,9</sup> Final cementations were done using resin cements because crown breakage rate has been high when cemented with traditional dental cements.<sup>10</sup> Cementation of the restoration is probably the most strict procedure, therefore dentists should follow manufacturer's instruction to ensure long lasting restorations. The patient was advised to seriously care for the restored teeth, regularly do dental check-ups, and avoid overload teeth contacts as these would harm the restorations and teeth underneath.

In conclusion, esthetic rehabilitation can be done successfully on crowded and protruded anterior dentition. Endodontic treatment, cast posts, and all ceramic crowns were used to improve patient's appearance where instant result could be achieved by this treatment. This is also supported by the fact that dentists should be aware of not only choosing the right treatment and materials but also patient's expectations and conditions. The growing popularity and demand for esthetic rehabilitation will in fact encourage dentists to be able to provide the supply as well as educating patients about realistic expectations for the corresponding esthetic restorations. Since there are many different philosophies and technologies that can be applied to esthetic rehabilitation cases, dentists must enrich themselves with thorough understanding about recent technologies and materials, and with that would come a greater ease in providing esthetic services with satisfactory results for the patients.

## REFERENCES

1. Spear FM, Kokich VG, Mathews DP. Interdisciplinary management of anterior dental esthetics. *J Am Dent Assoc* 2006; 137(2):160-9.
2. Powers JM, Sakaguchi RL. *Craig's restorative dental materials*. 12<sup>th</sup> ed. Philadelphia: Elsevier Inc; 2006. p. 454-6.
3. Roulet JF. Indirect aesthetic restorations. *Journal of Advances in Aesthetic and Restorative Dentistry* 2003; 5:15-9.
4. Shillingburg HT, Hobo S, Whitsett LD, Jacobi R, Brackett SE. *Fundamentals of fixed prosthodontics*. 3<sup>rd</sup> ed. Chicago: Quintessence Publishing; 1997. p. 433-6.
5. Prasetyo EP. Esthetic management for anterior teeth: a case report. Jakarta: APDC Publishing; 2007. p. 123.
6. Summitt JB, Robbins JM, Hilton TJ, Schwartz RS. *Fundamentals of operative dentistry: a contemporary approach*. 3<sup>rd</sup> ed. Chicago: Quintessence Publishing; 2006. p. 571-84.
7. Shabahang S. State of the art and science of endodontics. *J Am Dent Assoc* 2005; 136(1): 41-52.
8. Finke PM. The all ceramic system of the future. *Journal of Advances in Aesthetic and Restorative Dentistry* 2003; 7: 25-6.
9. Robeson TM, Heyman HO, Swift EJ. *Sturdevant's art and science of operative dentistry*. 5<sup>th</sup> ed. Philadelphia: Mosby Inc; 2006. p. 610-1.
10. Christensen GJ. The state of the art in esthetic restorative dentistry. *J Am Dent Assoc* 1997; 128(9):1315-7.