DIFFERENT CLINICAL MANIFESTATION OF CEREBRAL LUPUS DUE TO DIFFERENT BRAIN INVOLVEMENT. A REPORT OF TWO CASES

Raihan*, Rizal Altway*, Niniek Soemiarso*, Sjaifullah Noer*, Ariyanto Harsono*, Fatimah Haniman**

ABSTRACT

Involvement of the nervous system in systemic lupus erythematosus (SLE) is frequent. The most often clinical manifestations include psychosis, mood disorders, seizure, acute confusional states, headache, cranial nerve palsies, ataxia, nystagmus, papilloedema, meningitis, tremor, cortical blindness, and coma. There are no specific laboratory or magnetic resonance imaging findings, making a proper diagnosis often difficult. We report two cases of cerebral lupus in a thirteen-year-old and ten and a half year old girl. The first case presenting with fever, headache, right hemi paresis, aphasia, and somnolence. Neither meningeal signs nor pathologic reflexes were found. CT-scan revealed a white matter infarction, symmetrical on frontal lobe, midline slight shift to the left, but cerebral bleeding was not noted. The diagnosis of SLE of this patient was based on malar rash, oral ulcers, pleuritic pain, neurological disorders, and positive anti-DNA antibody and ANA test. The second patient had been diagnosed lupus nephritis since 5 months ago. She was hospitalized because of dyspnea and behavioral disorder. CT-scan revealed severe brain atrophy. Both patients were treated with methylprednisolon pulse 30 mg/kg/day for three days and followed with oral prednisone 2 mg/kg/day. Both of these patients were discharge on good conditions.

Keywords: *Systemic Lupus Erythematosus, diagnosis, cerebral lupus, brain involvement, prednisolon, prednisone*

INTRODUCTION

Systemic Lupus Erythematosus is a chronic, inflammatory disease of the connective tissue. More than 50% of all patients with SLE suffer from neurological involvement. A previous study reports that 25-75% of SLE patients have neuropsychiatric manifestations at some stage of their illness (King, 1998). Most often, acute central nervous system (CNS) involvement occurs early in the natural history of childhood SLE (Uziel, 1998). The most often observed manifestations include seizures, cranial nerve palsies, ataxia, nystagmus, papilledema, meningitis, tremor, cortical blindness, and coma. Neuropsychiatric manifestations including psychosis and personality disorder may also occur (King, 1998). No single objective test for the presence of CNS-SLE is accurate in childhood (Uziel, 1998). The diagnosis of cerebral SLE, even in adults, is easily overlooked in the absence of more widespread systemic involvement by the disease. In children there is an even greater likelihood of misdiagnosis because of the rarity of the disorder in this age group (King, 1998). Controversy exists as to the best approach for treatment. For severe CNS manifestations, pulse methylprednisolone therapy often is effective (Kajs-Wyllie, 2002). The purpose of this paper is to report a different clinical manifestation of cerebral lupus in a thirteen year old and a ten and a half year old girl.

**Department of Child Health,*
***Department of Psychiatry,*
Airlangga University School of Medicine
Dr. Soetomo Hospital Surabaya

CASE REPORT

Case 1

H, a thirteen-year-old girl was hospitalized in Department of Pediatric Dr. Soetomo Hospital on October 31st 2002 with main complaint of fever for two weeks before admitted. The fever was high in overtime and could not be overcome with anti pyretic. She got nausea, vomiting, stomachache focused on epigastrium region, loss of appetite, and constipation since two weeks ago. Her condition was getting worse in the last three days. Seven hours before admitted, she got short breathing and chest pain.

Physical examination on admission revealed an alert girl, looked very weak, irritable, pale and dyspneic, with body weight 38 kg, the blood pressure 90/50 mmHg, pulse rate 120 x/minute, respiratory rate 40 x/minute, and the temperature 40oC. There was anemia, but no jaundice, nor cyanosis. The heart and lung were normal. The liver enlarges 2 x 2 x 2 cm but the spleen was not palpable. Other abnormalities in her abdomen were not found. Her peripheral perfusion was good.

The laboratory examinations revealed: hemoglobin 3.5 g/dL, hematocrit 10%, WBC 4.800/mm3, platelet 217.000/mm3, MCV 94.3 FI (80-93), MCH 33 Pg (27-31), MCHC 35 g/dL (32-36), differential count -/-/1/68/29/2, erythrocyte sedimentation rate 160 mm/hour, reticulocyte 89‰ (5-20). AST 80 IU (0-19), ALT 36 IU (0-17), bilirubin direct 0.7, bilirubin indirect 2.3, albumin 2.9 g/dl, BUN 30 mg/dl, creatinin serum 1.2 mg/dl. From blood smear revealed: erythrocyte was hypochrom anisocytosis; leucocyte was normal count, no blast cell; platelet was normal count. Chest roentgenogram showed cardiomegaly with 60% of CTR. Electrocardiogram was normal.

The patient was diagnosed as febrile observation with suspicion of typhoid fever, sepsis and severe hemolytic anemia. She was treated with 5% dextrose and half saline 1700 cc/24 hours' intravenous fluid drip, ceftriaxone 2 x 1 gr intravenously, and transfusion of packed red cell. Further examinations to establish the diagnosis were performed. The examination included repeat complete blood count, blood smear and reticulocyte count at Pediatric Hematology Laboratory, complete urine and feces examination, serologic test of Widal and Gall culture, blood, urine and feces culture, echocardiography and CRP.

On the 4th day of hospitalization, the fever still present. She was alert, irritable and looked pale, but no vomiting nor dyspnea anymore. The result of blood examination revealed hemoglobin 8.8 g/dL, hematocrit 25.6%, WBC 2.100/mm3, platelet 115.000/mm3, differential count -/-/-/48/50/2, erythrocyte sedimentation rate 103 mm/hour. Feces and urine examination were normal. Widal: O 1/100, negative Gall culture and CRP. No pericardial effusion on echocardiography.

Based on clinical, laboratory and other finding examinations, suspicion of typhoid fever was ruled out. Until seven days hospitalization, the patient still got fever and complains of joint pain. We found something like rash on her both cheeks and oral ulcers were noted. There was no history of bleeding during hospitalization. We did repeated anamnesis to her mother about the clinical course of her illness. According to her, the patient suffered from joint pain predominantly large joints of upper and lower extremities since two and a half weeks before admission. There were no swelling, redness nor painful on motion. She noticed that the patient had slight behavioral changes, more sensitive than usual, lack of school performance and activities since the last 2-3 months. Based on these findings suspicious of systemic lupus erythematosus was concerned. We performed some examinations to confirm the diagnosis such as ANA test, anti ds-DNA titer, serial LE cell, C3 complement, renal biopsy, microalbumine urine and CRP.

Laboratory examinations revealed: negative CRP and ANA test, anti ds-DNA titer 438.7 WHO units/ml (negative: 0-92,6 borderline: 92,6-138,9 moderate: 138,9-370,4 strong: >370,4), LE cell was negative (3 times examinations), C3 complement 69.1 mg/dl (82-160), microalbumine urine 291.5 mg/dl (<20). All of these findings confirm the diagnosis of systemic lupus erythematosus. For these reasons, antibiotic was stopped after 10 days administrations and treatment with prednisone was started.

On the 18th day of hospitalization, the patient looked healthy, no fever during the last 4 days, oral ulcers were improved, malar rash slightly subside, and the appetite was well. However, the patient complained of headache. Laboratory examinations revealed, hemoglobin 6.9 g/dL, WBC 8.300/mm3, platelet 240.000/mm,3 reticulocyte 10‰, erythrocyte sedimentation rate 8 mm/hour, BUN 50, creatinine serum 0.9.

On the 19th days of hospitalization, the patient's condition was suddenly worse. She suffered from fever again and somnolence. The right side extremities could not be moved. Meningeal signs were not found. The result of blood test showed hemoglobin 5.9 g/dl, WBC 16.200/mm3, platelet 244.000/mm3, BUN 14 mg/dl, creatinine serum 0.9 mg/dl. Urine examination was normal. Based on this condition, diagnosis of SLE with central nervous system involvement was concerned. CT-scan was planned to confirm the diagnosis. The result showed a white matter infarction on middle lobe, midline slight shift to the left, but no sign of bleeding (Figure 1). Then the patient was treated with methylprednisolone pulse 30 mg/kg/day in 3 consecutive days and, continued with prednisone orally after that, and given blood transfusion.

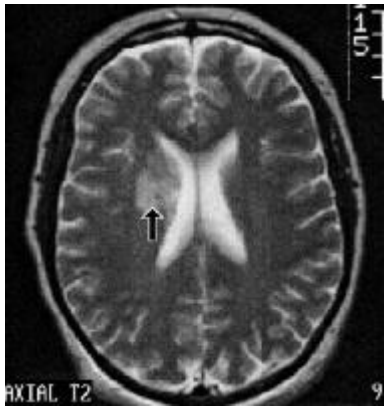

Figure 1. Result of CT-scan showing area of infarction on middle lobe with no sign of bleeding.

After 3 days therapy of methylprednisolone pulse the patient became stable. She still got right hemiparese and aphasia when discharge from the hospital. She could walk and speak fluently after one month follows up. Treatment with prednisone 40 mg alternate morning dose and azathioprine 50 mg once daily were continued.

Case 2

N, a ten and a half year old girl was hospitalized in Department of Pediatric Dr. Soetomo Hospital on January 5th 2005 with main complaint of dyspnea, and behavioral disorder. The dyspnea occurred suddenly since one day before admitted. According to her mother, the patients had behavioral changes a few days before admitted. She looked confused, just sitting without doing anything and did not pay attention to others. She did not want to sleep because when closing her eyes she saw blood came out from her hands. At the time she still recognize her parents, but later becoming less speech even don't know her parents.

She had been diagnosed lupus nephritis since four months ago. The diagnosis was based on malar rash, oral ulcers, hematological disorder, positive anti ds-DNA, positive ANA test, C3 complement < 30 mg/dl, and positive LE cell. From renal biopsy was found a focal proliferative glomerulonephritis appropriate with WHO class III of lupus nephritis. She had been treated with cyclophosphamid pulse 500 mg/m2 for 4 cycles.

Physical examination on admission revealed an alert girl but irritable with body weight 21 kg, the blood pressure 80/50 mmHg, pulse rate 126 x/minute, respiratory rate 42 x/minute, and the temperature 38oC. She looked dyspneic and anemic. Neither jaundice nor cyanosis was noted. There was found sub costal retraction on the chest, but heart and lung were normal. No enlargement of liver and spleen. Other abnormality on her abdomen was not found. Her peripheral perfusion was good. The meningeal signs or pathologic reflexes were not found. Laboratory examinations revealed: hemoglobin 9 g/dL, hematocrite 27%, WBC 6.300/mm3, platelet 112.000/mm3, blood glucose 114, BUN 8, creatinine serum 0.82, albumin 2.5, sodium 125 and potassium 3.21. There were 10-12 leucocytes on urine examination. Chest roentgenogram showed cardiomegali with 58% of CTR and pleural effusion. Electrocardiography result was a sinus tachycardia 150x/minute. There were no pericardial effusion signs on echocardiography.

The patient was diagnosed as lupus nephritis, urinary tract infection and suspicious of cerebral lupus. She was treated with 5% dextrose and half saline 1000 cc/24 hours intravenous fluid drip, ceftriaxone 2 x 1 gr intravenously, methylprednisolone pulses 30 mg/kg/day for 3 days, furosemide 3 x 30 mg intravenously. The patient was planned to perform head CT-scan, repeat complete blood count, culture of blood and urine, and also consulted to psychiatric department. .

On the 3rd day of hospitalization, she was getting better, dyspneic subside. The result from blood and urine examination revealed hemoglobin 10.9 g/dL, WBC 8.900/mm3, platelet sufficient in number, differential count -/-/-/87/13, sodium 132. Urine examination: leukocyte 4-5. There was no bacterial growth on urine and blood culture. The treatment was continued. Assessment from Psychiatric department was an organic mental disorder.

On the 4th day of hospitalization, the patient was getting better, no fever nor dyspneic anymore, the appetite was well, but still irritable and sometimes still talking

unmeaning words. Intravenous fluid drip of 5% dextrose and half saline 1000 cc/24 hours and furosemide intravenously were stopped and treatment with prednisone 2 mg/kg/day was started. CT-scan examination showed severe brain atrophy (Figure 2).

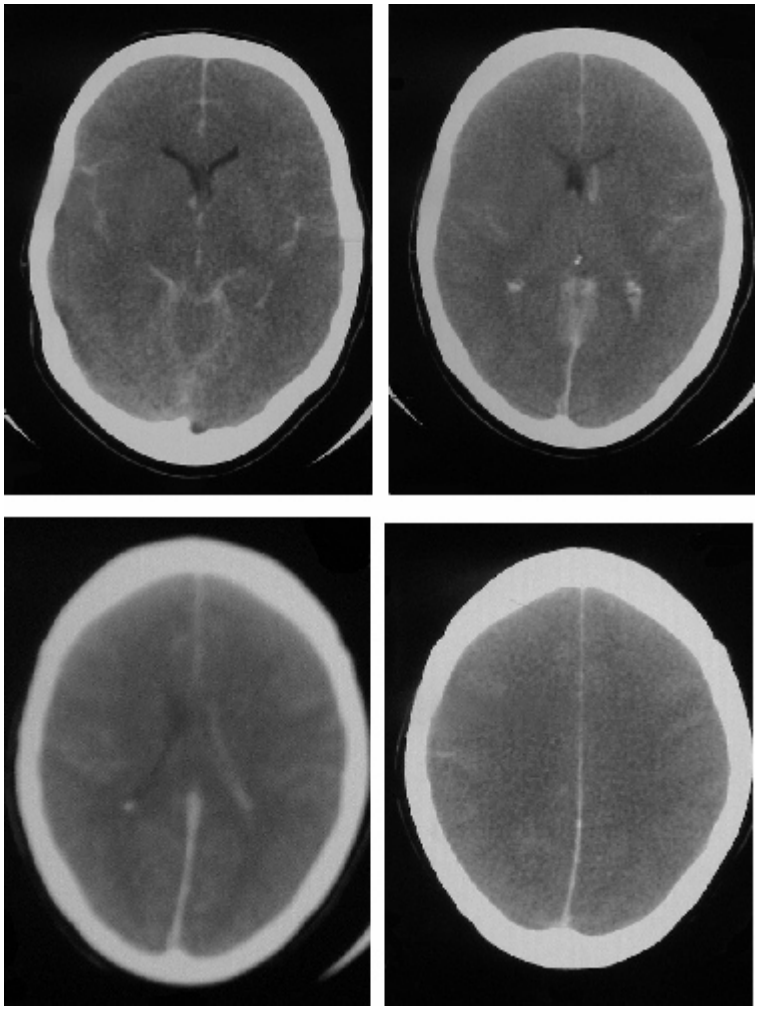

Figure 2. SC-Scan showing severe brain atrophy.

Laboratory examinations on the 10th day of hospitalization revealed hemoglobin 8.5 g/dL, WBC 2.100/mm3, platelet sufficient in number, differential count -/-/-/87/13/-, and positive CRP. Ceftriaxone intravenously was still given to the patient. In general the patient looked well, but her hands became tremor even when she was resting. She walked around the room without right purpose. Psychiatric department assumed that the organic mental disorder was because of severe brain atrophy due to SLE itself.

On the 15th day of hospitalization, the patient was given the fifth cyclophosphamide pulse 500 mg/m2. The last laboratory results were hemoglobin 12.2 g/dL, WBC 2.100/mm3, platelet sufficient in number, differential count -/-/-/80/20/-, normal urinalysis, and negative CRP. Based on these result antibiotic was stopped. The patient was discharge from hospital after 17 days hospitalization without active signs of SLE.

DISCUSSION

Systemic Lupus Erythematosus (SLE) is a connective tissue disease characterized by multiple organ inflammation. Clinical course in each individual varies with tendency toward quiescence remission and relapse (Kasitanon, 2000). Clinical manifestations in children

most frequently present with fever, fatigue, athralgia or arthritis and rash. Symptoms maybe intermittent or persistent (Klein-Gitelman, 2004). According to the American College of Rheumatology, for a diagnosis of SLE, the patient must have at least four of the following organ involved: renal (proteinuria or cellular casts in urine), thoracic/cardiac (pleurisies with or without pleural effusion; pericarditis, cardiomegaly, myocarditis, heart failure), skin (malar or discoid rash), joint (arthritis), hematological system (anemia, thrombocytopenia, neutropenia), or brain and spinal cord (seizure, psychosis, myelitis). (Wallace, 1998; Klein-Gitelman, 2004; Keane 2000).

Antinuclear antibody (ANA) test is often present in children with active SLE and present in 98% of patients (Sultan, 1999; Dean, 2000). However ANA test can be found without any disease or can be associated with rheumatic and other conditions. A positive ANA test result is not required for diagnostic; however its absence is rare (Epstein, 1999; Pickering, 2000). The presence of large amount of serum antibodies to double-stranded DNA is specific for SLE (Klein-Gitelman, 2004; Dean, 2000; Epstein, 1999). Serum level of total hemolytic complement (CH10), C3 and C4 decrease in active disease provide a second measure of disease activity (Klein-Gitelman, 2004; Pickering, 2000). Anti Smith antibody is only found in patients with SLE, does not measure disease activity (Sfikakis, 1998). Renal biopsy is used to confirm diagnosis of lupus nephritis and to determine treatment (Sfikakis, 1998; Weiner, 2000).

The first patient on our case got malar rash, oral ulcers, pleuritic pain, arthritis, hematologic disorders, neurologic disorders, and positive anti ds-DNA and ANA test. While the second patient was diagnosed nephritis lupus based on malar rash, oral ulcers, hematologic disorder, neurologic disorder, renal disorder (proteinuria, hematuria, cellular casts), positive anti ds-DNA and ANA test, C3 complement < 30 mg/dl, positive LE cell, and was found a focal proliferative glomerulonephritis appropriate with WHO class III of lupus nephritis on renal biopsy. Because both of these patients presented more than 4 of 11 ARA classification criteria's, diagnosis of SLE in the first case and nephritis lupus in the second case were made. During the course of their illness, our patients showed cerebral nervous system involvement with different neuropsychiatric manifestations for each other.

Cerebral lupus may present as seizure, psychosis, myelopathy, or stroke in a patient with SLE. A neurological disorder may occur as an isolated event or in association with other systemic signs of SLE or even precede the onset of systemic disease. The duration of CNS involvement may vary from a few minutes to years (Rovaris, 2000; Kajs-Wyllie, 2002). Neurological signs of cerebral are categorized into focal, non-specific, and neuropsychiatric (Table 1). (Kajs-Wyllie, 2002).

Table 1. Neurological manifestations of lupus cerebritis (Kajs-Wyllie, 2002)

Focal	**Non-specific**	**Neuropsychiatric**
Transient ischemic Attack/stroke	Headache - Vascular - Muscular	Affective - Personality disorders - Irritability
Transverse myelitis		- Anger
	Seizures	- Anxiety
Cranial nerve palsies	- Tonic/clonic	- Depression
- Laryngeal palsy		- Sadness
- Visual loss	Organic brain syndrome	- Hopelessness
- Ptosis		
- Facial weakness		Behavioural - Crying
Peripheral neuropathy		- Apathy
- Numbness/tingling		- Poor eye contact
- Facial pain		- Lack of initiative
- Tinnitus		
		Cognitive
Movement disorders		- Difficulty thinking, concentrating, or speaking
- Chorea		
- Cerebellar ataxia		- Fluctuating level of consciousness

Our first case suffered from headache, unconsciousness, hemiparesis, and aphasia. These symptoms and signs appeared on the 19th days of hospitalization, after 2 weeks was diagnosed as SLE. The second case was present predominantly neuropsychiatric manifestations such as personality disorders, irritability, anxiety, depression, crying, apathy, poor eye contact, difficulty concentrating and speaking. Psychiatric department supported the diagnosis with assumed that organic mental disorder of this patient due to SLE itself. Cerebral lupus on the last case occurred after 4 months of nephritis lupus was established.

Precise diagnosis of cerebral lupus is extremely difficult. In children there is an even greater likelihood misdiagnosis because of the rarity of the disorder in this age group ((Uziel, 1998; Klein-Gitelman, 2004). There is no single diagnostic gold standard. Most of all recommended that diagnosis should be based on both clinical assessment as well as the presence of antibodies in the serum and CSF. A diagnosis of cerebral lupus cannot be made from radiologic finding alone, because true vasculitis is rarely seen radiologically. Various imaging studies that aid in diagnosing cerebral lupus have been reported such as computed tomography, magnetic resonance imaging, electroencephalography, cerebral blood flow, positron emission tomography/single photon emission computed tomography, transcranial doppler, and cerebral angiogram (Kajs-Wyllie, 2002).

Imaging studies that performed on both of our cases were computed tomography. CT-scan findings on the first case showed a cerebral infarction. Cerebral infarction in SLE patient suggested as manifestation of cerebral vein thrombosis (CVT) or cerebral vasculitis. Because in this patient clinically her consciousness decrease abruptly, had right hemiparesis and aphasia, CVT is more likely as the cause.

The second case showed severe brain atrophy on CT-scan examination, with behavioural disorder as the main symptom. Interestingly, two cases of cerebral lupus with different clinical manifestations seem likely due to different brain involvement as shown by CT scan. Because there is no one specific laboratory test available to diagnose cerebral lupus, diagnosing the condition remains a challenge. CSF studies may be used, because they show high protein levels in 40%-80% of patients with CNS manifestations of SLE. CSF also can be tested for the presence of IL-6 and interferon alfa, because their levels are found to be significantly higher in SLE patients who develop neurological symptoms. Specific antibodies that target parts of the neuron and confirm CNS involvement are intracytoplasmic-targeted antibodies (anti ribosomal P, anti Ro, SS-A or anti-La, SS-B). Their presence is seen in both the CSF and serum of patients with cerebral lupus (Dean, 2000). The presence of antiphospholipid antibodies, lupus anticoagulant and anticardiolipin, correlates with changes in the patient's CT/MRI. Lupus anticoagulant was seen in the serum of 34% of patients and anticardiolipin antibodies were seen in the 44%-50% of patients (Rood, 2001).

Neuron reactive autoantibodies are considered a much better marker for CNS involvement, with levels significantly higher in cerebral lupus. Specifically, lympho-cytotoxic antibodies (LCAs) are seen in 80% of patients. Assessments of complement components (C3 and C4), which are part of the coagulation cascade, show low serum and CSF concentrations (Seaman, 1999; Male, 1999; Molta, 1998). We only performed complement component (C3) to both of the cases. The result of this examination showed low serum of C3 (69.1 mg/dl, <30 mg/dl respectively). The exact pathophysiologic process of CNS involvement in SLE is unknown (Karassa, 2000; Dungan, 1999). The proposed mechanisms that are likely due to the assault of several autoimmune system changes include circulating immune complexes, anti-neuronal antibodies, antiphospholipid antibodies, and cytokine release. No one clear mechanism appears to cause cerebral lupus. All mechanism may present or act independently (Kajs-Wyllie, 2002; Rood, 2001; Rood, 1999).

The immune complexes, which consist of DNA and anti-DNA, cause an inflammatory response as well as a disruption of the blood brain barrier. These circulating complexes have been found trapped in the highly vascular choroids plexus of SLE patients upon autopsy. True vasculitis, however is found only in about 10% of patients with cerebral lupus (Kajs-Wyllie, 2002; Rood, 1999).

The three identified anti-neuronal antibodies postulated in CNS involvement are the lympho-cytotoxic antibodies (LCAs), which somehow react with brain tissue and interfere with the neuron's ability to respond. These antibodies also correlate with cognitive and visual spatial defects. Second, the anti-neuronal membrane antibodies are targeted directly to neuronal antigens. And third, the intracytoplasmic antibodies target the constituents of the neuron cells (i.e., ribosomes and neurofilaments). They are also called anti-SSA or anti-SSB antibodies. These antibodies are seen in 99% of SLE patients with psychosis. Those antibodies mentioned above are found in CSF and serum patients with cerebritis (Rood, 2001; Rood, 1999).

Another mechanism of CNS involvement is the thrombosis associated with antiphospholipid antibodies. The two antibodies implicated are anticardiolipin and lupus anticoagulant. Anticardiolipin antibodies attach to the endothelial lining of cells, causing endothelial damage, platelet aggregation, inflammation, and fibrosis. The lupus anticoagulant antibody prolongs coagulation (Kajs-Wyllie, 2002).

The final mechanism of cerebral lupus involves the cytokines. The cytokines trigger oedema, endothelial thickening, and infiltration of neutrophils in brain tissue. Two cytokines, interferon alpha and interleukin-6, have been found in the CSF of SLE patients with psychosis (Dean, 2000; Kajs-Wyllie, 2002). We did not perform any specific antibodies examination to both cases; therefore, we could not be sure the proposed mechanism to cause cerebral lupus in these cases.
Most children and adolescents with SLE will require treatment with corticosteroids in order to control disease and prevent damage; often the dosage required are high and associated with serious side effects (Tucker, 2002). The optimal dose and route of administration of corticosteroids are controversial. Patients with systemic disease are often started with 1-2 mg/kg/24 hours of oral prednisone in divided dose. When complement levels arise within the normal range, the dose is carefully tapered over 2-3 years of the lowest effective dose. Severely ill patients may required pulse intravenous corticosteroid therapy (30 mg/kg/dose), not greater than 1 gram, is given over 60 minutes once per day for 3 days (Kajs-Wyllie, 2002). Physicians generally agree to begin immunosuppressive therapy early in the course of disease for a child with biopsy-proven diffuse proliferate glomerulonephritis, disease of the CNS or a pulmonary hemorrhage, situations where the risk for disease damage is severe and well defined.

In general, immunosuppressive therapy should be strongly considered for a child with SLE in whom the prednisone dose cannot reduce to a once-daily dose of < 0.5 mg/kg/day after 6 months of therapy. Even when the need for immunosuppressive therapy is agreed upon, the choice of drug remains controversial. This is not surprising considering the potential toxicity of drugs such as cyclophosphamide and azathioprine (Tucker, 2002). Both of our cases initially were treated with 60 mg/m2/day (2 mg/kg/day) of oral prednisone. The first case gave a good result: no fever anymore, oral ulcers were improved, malar rash slightly subside, and joints pain were disappeared. However, after 2 months therapy in the second case, signs and symptoms of nephritis lupus did not have an expected progress. It still showed protein, blood and casts on urine examination. Therefore, treatment with cyclophosphamide pulse 500 mg/m2 was started. This treatment gave an improved nephritis lupus itself. It seem that cyclophosphamide pulse treatment can control the nephritis lupus per se, but not strong enough to prevent cerebral lupus. So when both patients got CNS involvement's manifestations, metylprednisolon pulse 30 mg/kg/day was given for 3 consecutive days and then followed with oral prednisone 2 mg/kg/day. The first case was continued with azathioprine 50 mg once daily when discharge from hospital to prevent more organ damage and disease activity; while the second case had been treated with cyclophosphamid pulse 500 mg/m2 5 cycles previously, prednisone 40 mg/day, and neuropsychiatry drugs.

Treatment also remains controversial in the young patient with cerebral infarction. It has been suggested that these patients should be placed an oral anticoagulant with warfarin. However, there is concern with regard to anticoagulation of children with warfarin for acute arterial occlusions, especially the risk of hemorrhagic complications (Dungan, 1999). Neither the first nor the second case was given oral anticoagulant although the first case got cerebral infarction. According to the literature, CNS involvement ranks second to renal failure as cause of death in the patient with SLE. Prognosis is guarded because the multisystem involvement of lupus can continue with exacerbations and remission. Resulting neurological deficits may be transient or permanent, occasionally resulting in death (Kajs-Wyllie, 2002). The first patient left hospital still with hemiparesis and aphasia. One month later she could walk and speak fluently. While the second patient discharge from hospital with concentration and memory deficits. Unfortunately, she never comes to outpatient clinic for further follow up until this time.

SUMMARY

Two cases of cerebral lupus with different clinical manifestations had been reported. The first case suffered from headache, unconsciousness, hemiparese, and aphasia. The second case was present predominantly neuropsychiatry manifestations such as personality disorders, irritability, anxiety, depression, crying, apathy, poor eye contact, difficulty concentrating and speaking, and movement disorder. Proposed mechanism of CNS involvement in SLE is circulating immune complexes, anti-neuronal antibodies, antiphospholipid antibodies, and cytokine release. We do not know exactly about the proposed mechanism to cause cerebral lupus in both of our cases. No one diagnostic test is conclusive of the CNS involvement in SLE; however clinical manifestations support diagnosis. Diagnosis of cerebral lupus in our cases was made based on clinical manifestations, laboratory and radiographic findings.

Treatment cerebral lupus in our cases included corticosteroids and immunosuppressive therapy.

REFERENCES

Dean GS, Tyrrel-Price J, Crawley E, Isenberg DA, 2000. Cytokines and systemic lupus erythematosus. *Ann Rheum Dis* 59, pp. 43-51.

Drenkard C, Alcaron-Sergovia D, 2000. The new prognosis of systemic lupus erythematosus: treatment-free remission and decreased mortality and morbidity. *IMAJ* 2, pp. 382-7.

Dungan DD, Jay MS, 1999. Stroke in an early adolescent with systemic lupus erythematosus and coexistent antiphospholipid antibodies. *Pediatrics* 90, pp. 96-8.

Epstein HF, 1999. Antibodies to DNA. *N Engl J Med* 338, pp. 1359-67.

Kajs-Wyllie M, 2002. Lupus cerebritis: a case study. *J Neuroscience Nurs* 34 cited from http/www.CE Lupus Cerebritis a Case Study.htm.download April 15,2005, 11:00 am.

Karassa FB, Ionnidis JPA, Touloumi G, 2000. Risk factors for central nervous system involvement in systemic lupus erythematosus. *Q J Med* 93, pp. 169-74.

Kasitanon M, Louthrenoo W, Sukitawut W, 2002. Causes of death and prognostic factors in Thai patients with systemic lupus erythematosus. *Asia Pacific J Allergy Immunol* 20, pp. 85-91.

Keane MP, Lynch III JP, 2000. Pleuropulmonary manifestations of systemic lupus erythematosus. *Thorax* 55, pp. 159-66.

King J, Aukett A, Smith MF, 1998. Cerebral systemic lupus erythematosus. *Arch Dis Child* 68, pp. 968-70.

Klein-Gitelman MS, Miller ML, 2004. Systemic lupus erythematosus. In: Behrman RE, Kliegman RM, Arvin AM, Eds. *Nelson Textbook of Pediatrics*, 18th ed. Philadelphia: WB Saunders Company, pp. 713-7.

Male C, Lechner K, Eichinger S, 1999. Clinical significance of lupus anticoagulants in children. *J Pediatr* 134, pp. 199-205.

Molta C, Meyer O, Dosquet C, 1998. Chilhood-onset systemic lupus erythematosus: antiphospholipid antibodies in 37 patients and their first-degree relatives. *Pediatrics* 92, pp. 849-53.

Pickering MC, Walport MJ, 2000. Links between complement abnormalities and systemic lupus erythematosus. *Rheumatology* 39, pp. 133-41.

Sfikakis PP, Mitsikostas DD, Manoussakis, 1998. Headache in systemic lupus erythematosus: a controlled study. *Br J Rheumatol* 37, pp. 300-3.

Rood MJ, Haverman JF, van Duinen SG, 2001. CNS involvement in systemic lupus erythematosus: a case with remarkable histopathological findings. *Ann Rheum Dis* 60, pp. 299-300.

Rood Mj, Keijsers V, van der Linden MW, 1999. Neuropsychiatry systemic lupus erythematosus is associated with imbalance in interleukin 10 promoter haplotypes. *Ann Rheum Dis* 58, pp. 85-9.

Rovaris M, Viti B, Ciboddo G, 2000. Brain involvement in systemic immune mediated disease: magnetic resonance imaging and magnetization transfer imaging study. *J Neurosurg Psychiatry* 68, pp. 170-7.

Seaman DE, Londino AV, Kwoh K, 1999. Antiphospholipid antibodies in pediatric systemic lupus erythematosus. *Pediatrics* 96, pp. 1040-5.

Sultan SM, Iannou Y, Isenberg DA, 1999. Review of gastrointestinal manifestations of systemic lupus erythematosus. *Rheumatology* 38, pp. 917-32.

Tucker LB, 2002. Controversies and advances in the management of systemic lupus erythematosus in children and adolescent. *Best Practise Res Clin Rheum* 16, pp. 471-80.

Urowitz MB, Gladman DD, 2000. How to improve morbidity and mortality in systemic lupus erythematosus. *Rheumatology* 239, pp. 238-44.

Uziel Y, Laxer RM, Blaser S, 1998. Cerebral vein thromboses in childhood systemic lupus erythematosus. *J Pediatr* 126, pp. 722-7.

Wallace DJ, Hahn BH, 1998. *Dubois' lupus erythematosus*. Philadelphia: Lippincot Williams & Wilkins, pp. 868-9.

Weiner SM, Otte A, Schumacher M, 2000. Diagnosis and monitoring of central nervous system involvement in systemic lupus erythematosus: value of F-18 fluorodeoxyglucose PET. *Ann Rheum Dis* 59, pp. 377-85.